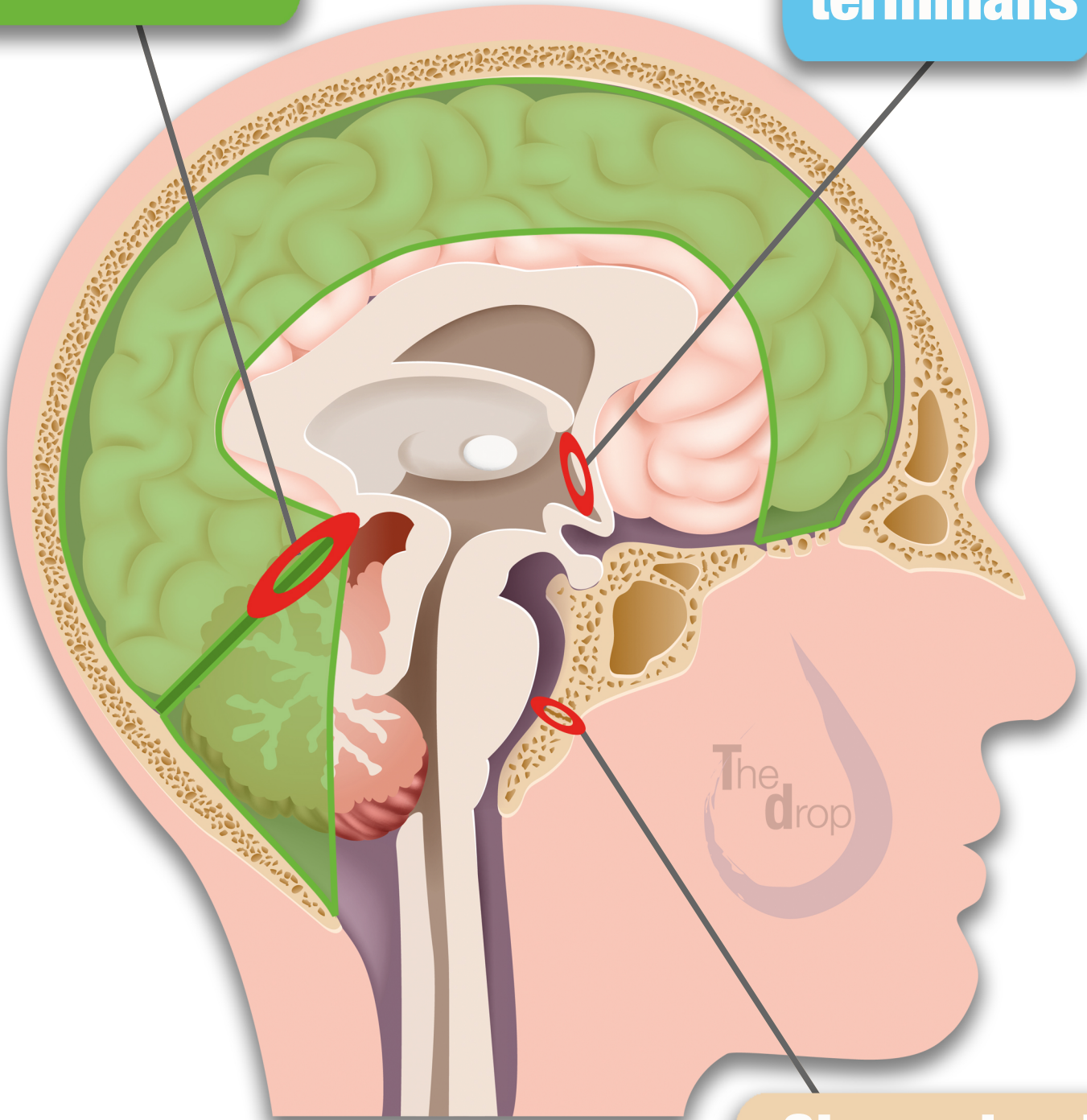


Fulcros naturales en la cabeza

Fulcro de Sutherland

Lámina terminalis



Sincondrosis esfeno-basilar

